

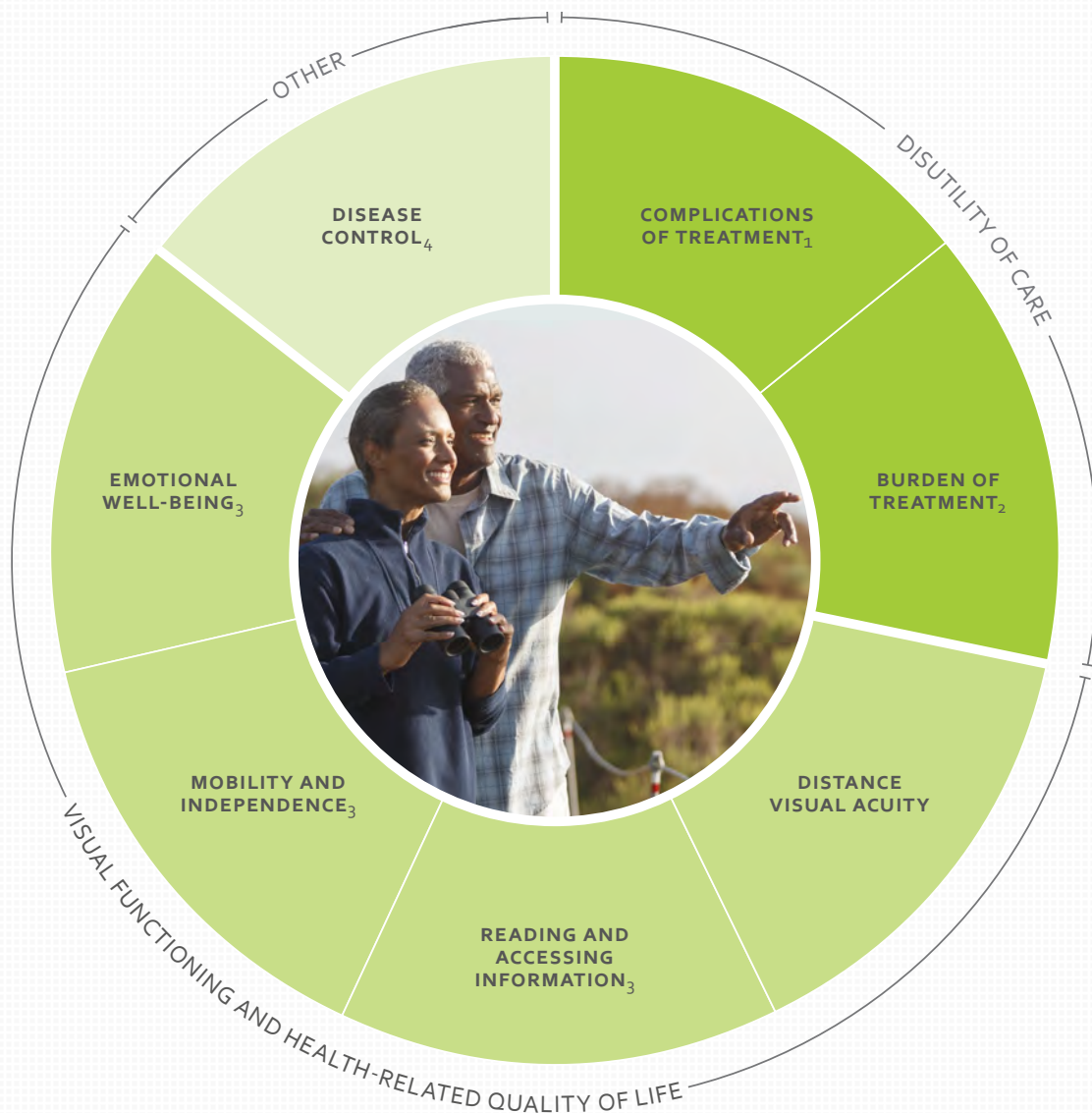ICHOM Set of Patient-Centered Outcome Measures for

MACULAR DEGENERATION

Treatment approaches covered

Intravitreal anti-VEGF treatment | Other intravitreal treatments | Photodynamic therapy | Thermal photocoagulation | Retinal radiation therapy
Transpupillary thermotherapy | Retinal surgical treatment

For a complete overview of this Set, including definitions for each measure, time points for collection, and associated risk factors, visit ichom.org/medical-conditions/Macular-Degeneration



Details

- 1 Endophthalmitis
- 2 Individual treatments received for macular degeneration
- 3 Recommended to track via the Brief Impact of Vision Impairment (B_IVI) Questionnaire
- 4 Presence of fluid, edema, or hemorrhage

 **ICHOM**
MACULAR
DEGENERATION

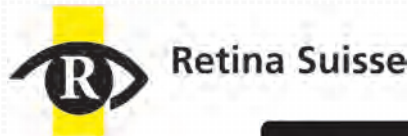
Revised: 24.01.2022

ICHOM Set

CONTRIBUTORS

For more information about the process of developing a Set of Patient-Centered Outcome Measures, visit ichom.org/how-we-work/

The Sponsors



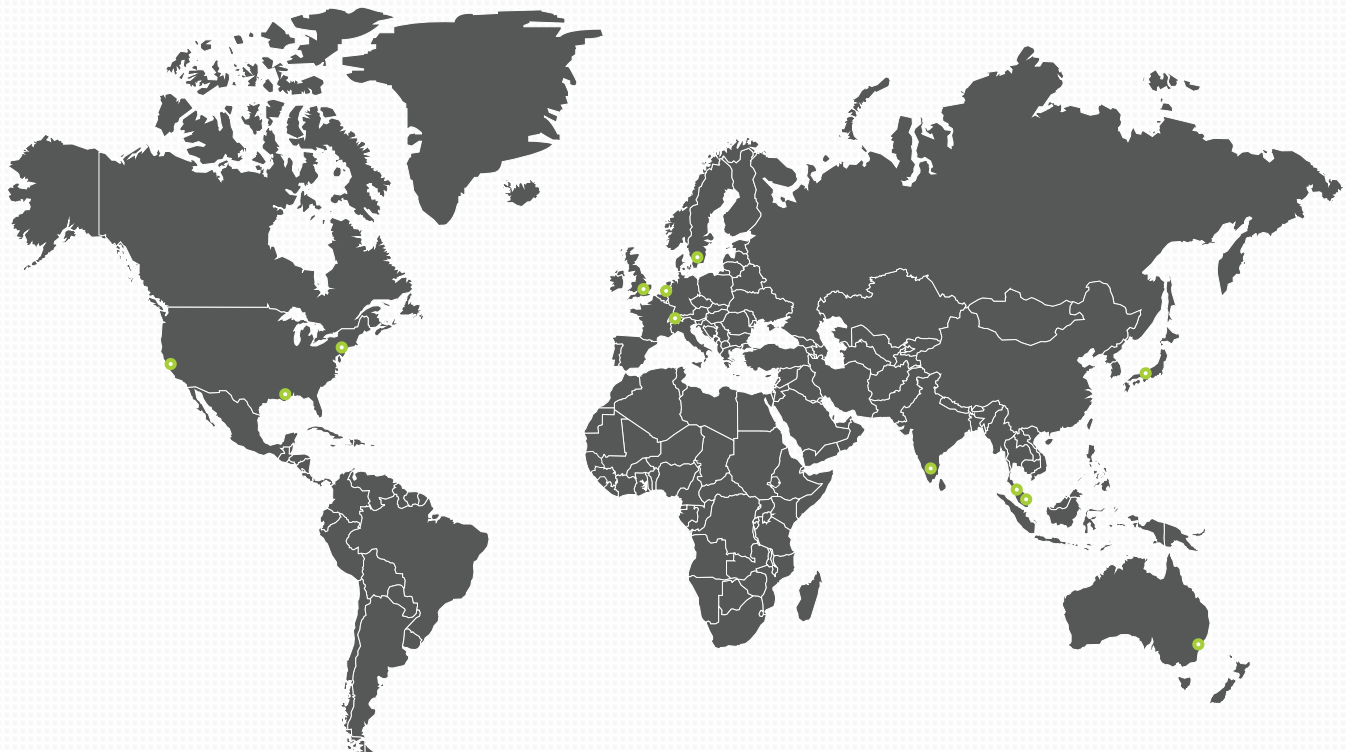
THE MACULA FOUNDATION
PRESERVING AND RESTORING VISION



The Retina Society



The Working Group



Australia

Mark Gillies | University of Sydney

India

Kim Ramasamy | Aravind Eye Care System

Japan

Nagahisa Yoshimura | Kyoto University
Hiroshi Tamura | Kyoto University

Malaysia

Norfariza Ngah | Hospital Selayang
Dato Shankar*

Netherlands

Caroline Klaver | Erasmus Medical Center

Singapore

Gemmy Cheung | Singapore National Eye Center

Sweden

Inger Westborg | Umeå University;
Registercenter Syd/EyeNet Sweden

Switzerland

Daniel Barthelmes | University Hospital Zurich

United Kingdom

Robert Johnston | Gloucestershire Hospitals
NHS Foundation Trust

Adnan Tufail | Moorfields Eye Hospital

Ian Rodrigues | St. Thomas' Hospital

Martin McKibbin | Royal College of Ophthalmologists

Cathy Yelf* | Macular Society

United States

Mark Blumenkranz | The Byers Eye Institute at Stanford University

Suzann Pershing | Stanford University;
American Academy of Ophthalmology; VA Palo Alto Health Care System

Christina Weng | Baylor College of Medicine

Julia Haller | Wills Eye Hospital; Thomas Jefferson University

*Patient representative